

GastroIntestinal Color Space and Its Application to Image Enhancement

HAI VU, TOMIO ECHIGO,^{†2} KEIKO YAGI,^{†3} MASATSUGU SHIBA,^{†4}
TOSHIO WATANABE,^{†4} KAZUNARI TOMINAGA,^{†4} TETSUO ARAKAWA^{†4}
and YASUSHI YAGI^{†1}

Color is a robust feature in computer assisted diagnosis of Video Capsule Endoscopy (VCE). This paper proposes a color space, specific to the human Gastrointestinal (GI) tract. A statistical model is constructed from a large VCE dataset, in which color components are classified into three groups: GI wall, darkness, and noise. The main cues for the clustering task are visualizing the appearance of color components and the frequency thereof. To utilize these features, a Self-Organizing Map (SOM) is deployed in a two stage semi-supervised scheme. We show the effectiveness of the proposed GI space in an application of image enhancement. With prior information about available colors from the GI color space, the enhancement task turns to increasing to the maximum color contrasts in the color range of the original image. In this sense, the enhanced image preserves the natural color tones of the original image as far as possible. The experimental results show that 84% of the enhanced images exceed the baseline level and are feasible for deployment in clinical applications.

1. Introduction

Introduction of the capsule endoscopy technique⁵⁾ has provided numerous opportunities to examine diseases in the human Gastrointestinal (GI) tract, particularly suspicious regions in the small bowel. In support of examining doctors diagnosing Video Capsule Endoscopy (VCE), several computer aided techniques have been proposed, such as reducing diagnostic time¹⁴⁾, detecting abnormal regions²⁾, and segmenting digestive organs^{3),10)}. Despite many characteristics of the images being utilized in such systems, understanding appearances generally relies on approaches of common (or natural) im-

ages. Intuitively, dedicated models, which take into account distinct features of the GI tract images, could provide effective support methods as well as simple computational algorithm.

This paper investigates the color features of the GI tract and proposes a technique utilizing these results for capsule image enhancement. Color is the most popular feature for describing GI images^{2),3),9),10),14)}. Visually, color GI images have unique tones; for example, stomach images tend to consist of pinkish colors, while images of the small intestine are predominantly pinkish-yellow⁹⁾. To quantify these characteristics, a GI color space is constructed through a statistical model of image appearance from pixel data. Using a dataset comprising a large number of VCE sequences, color components are extracted and clustered into the three groups: GI wall, darkness, and noise (with the latter two groups referred to as non-wall components). Color appearances and the frequency thereof are the main features used for classification. A two stage semi-supervised scheme based on the Self-Organizing Map (SOM) is deployed. In the first stage, a coarse SOM is created and its nodes are manually assigned group labels. The number of nodes is then increased to form a fine map in the second stage. The nodes on the new map are automatically assigned according to the voting results from the coarse map. Consequently, the GI color space including only wall or non-wall color components is extracted and utilized as prior information in applications of capsule image enhancement.

Low LED illuminations, the darkness of lumen regions, and loop configurations in the GI tract are all causes of unclear images. On the other hand, pathologic findings in suspicious frames usually are faced to various type of abnormalities such as bleeding, ulcers, angiodysplasia, and so on. To assist medical doctors in these circumstances, we propose a new method for capsule endoscopy image enhancement using the GI color space. The main limitation of current technique (FICE mode in RapidReader Version 6.0 (RR6)⁴⁾), however, is that the enhanced images are generated from arbitrary color range that is usually non-related to the range in the original image. Consequently, the appearance of the enhanced image may cause over-diagnosis. Utilizing the proposed GI color space ensures full availability of GI colors in a certain range. In this sense, the enhancement task becomes one of increasing to the maximum the color contrast within the current color range. In contrast to FICE mode, the proposed technique preserves the color tones of the original image. With respect to implementation, the proposed

^{†1} Insitute of Scientific and Industrial Research, Osaka University. {vhai,yagi}@am.sanken.osaka-u.ac.jp

^{†2} Osaka Electro-Communication University, echigo@isc.osakac.ac.jp

^{†3} Kobe Pharmaceutical University

^{†4} Graduate School of Medicine, Osaka City University

technique is inspired by the conventional histogram equalization technique transforming original pixel data to a new uniform distribution. Efficiency of the proposed technique is validated by experts through extensive evaluations in experiments.

2. The GI Color space

2.1 Material and generic GI color space

Intuitively, constructing a consistent GI color space requires a large dataset of VCE sequences to cover a variety of patient data. In this study, we selected 30 sequences (each containing about 57,000 frames) from a database containing data for 300 patients, taking care in selecting a wide range of ages, both genders and varying lengths of video sequences. Subsequently, a large dataset containing $\approx 107 \times 10^9$ images was quantized using the popularity color algorithm. For an original RGB image (256 x 256 pixels), each color channel is divided into N bins to construct a global color histogram. The popularity algorithm simply selects the K color components with the highest histogram values. The components included in the space are uniquely collected from fully quantized data. The probability $P(\cdot)$ of a color component c_{rgb} is defined as:

$$P(c_{rgb}) = \frac{H(c_{rgb})}{T}, \quad (1)$$

where $H(c_{rgb})$ is the total number of pixels belonging to color c_{rgb} and T is the total number of pixels in the dataset. $N = 32$ and $K = 256$ are optimal values.

Figure 1(a) shows the constructed color space in the original RGB space. To observe distributions of color components more easily, Fig. 1(b) shows $P(\cdot)$ plotted along the PC 1 and PC 2 axes, which are the primary components transformed from the original RGB space using Principal Component Analysis (PCA). Fig. 1(b) is also rendered using the true colors of the components.

2.2 Color Component Clustering

A capsule image usually comprises the wall regions visualizing surfaces of rugae in the GI tract; non-wall regions expressed as darkness, and other artifacts such as water bubbles, bile, food, etc. The visible texture of the GI wall has unique color tones, for example, the surface of the stomach is usually pinkish in color, whereas small intestine tissue contains villi with yellowish colors. In terms of statistical measurement, Fig. 1(b) verifies that with a large dataset, the probability $P(\cdot)$ of noise is very small, whereas the $P(\cdot)$ of wall regions and dark regions is more robust. Therefore, the appearance of

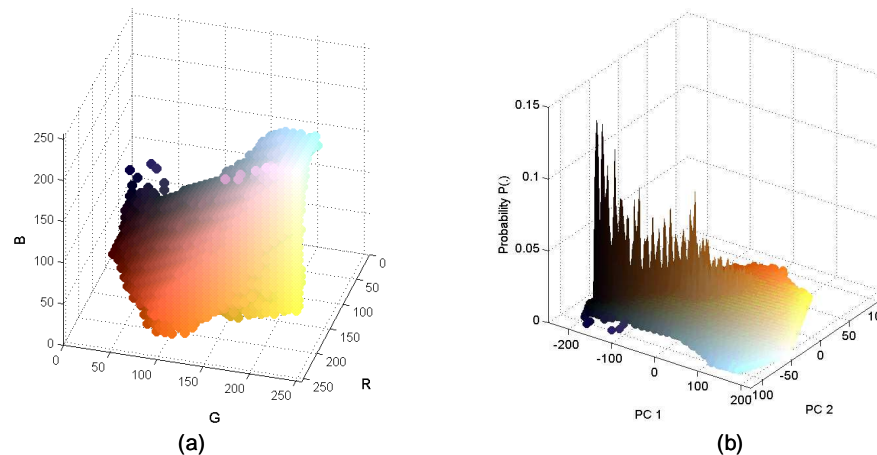


Fig. 1 (a) The original GI color space in RGB space. (b) Distribution of $P(\cdot)$ with the color components plotted in PCA space.

color and the probability thereof provide cue information to cluster color components, as listed in Table 1.

Because of the advantages of visualizing and clustering data, the use of the SOM technique⁶⁾ is fully justified. The SOM is an unsupervised technique that makes use of a two-dimensional grid map for data clustering. The main aim of the SOM is to adjust iteratively the weights connecting inputs to outputs, so that ultimately these reflect the distance relations between input patterns. In this study, the SOM technique is deployed as a two stage scheme. The main task in the first stage is to construct a coarse map that makes it easy to label color components. Then, the coarse map is fine-tuned in the second stage by increasing the size of the grid map.

Table 1 Criteria for clustering color components

Group (label)	Color Appearance	Probability
<i>GI wall (1)</i>	Close to wall regions (reddish to yellow)	High
<i>Noise (2)</i>	Water bubbles (white), food, gas ...	Low
<i>Darkness (3)</i>	Black or high intensity grey	High

The color component $x = [R \ G \ B]$ is an input vector used in training the SOM. First,

a simple map consisting of $j \times k$ nodes is created, in which the weights of nodes z_{jk} are randomly initialized. Then the distance d_{jk} between an input vector x and a map node z_{jk} is computed by:

$$d_{jk} = \sum_{i=1}^d (x_i - w_{jk,i})^2 \quad (2)$$

Based on the minimum distance of d_{jk} , a node which is Best-Matching Unit (BMU) is identified. Weights of the BMU and its neighborhood are adjusted by:

$$w_{jk,i}^{r+1} = w_{jk,i}^{(r)} + \eta(x_i - w_{jk,i}^{(r)}) \quad (3)$$

These steps are repeats until the stop conditions, in which the learning rate η and neighborhood radius r are updated after each iteration. Fig. 2(a) shows the data distribution of the randomly initialized nodes (in total, 25×25 nodes) in the GI color space (Fig. 1(b)) to construct a coarse map. The resulting SOM after 10 iterations is shown in Fig. 2(b). In more detail, each node in the resulting SOM is a representative of similar input vectors. Two example nodes are shown zoomed-in in Fig. 2(c). These illustrations were generated using the SOM Toolbox in Matlab¹³⁾.

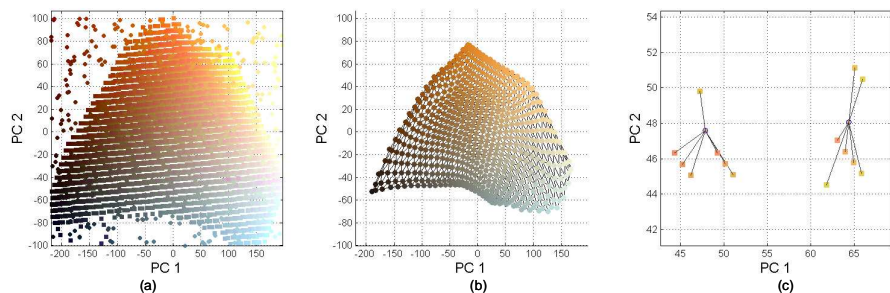


Fig. 2 (a) Distribution of random data (in circles) in the GI color space. (b). The coarse SOM resulting. (c) Two representative nodes connecting similar input vectors

Summing $P(\cdot)$ of the input vectors gives color distribution P_{jk} of the representative node:

$$P_{jk} = \sum_{i=1}^N P_i \quad (4)$$

where N is the number of input vectors connected to node z_{jk} . To express P_{jk} in the constructed map, the region within each node is utilized. Fig. 3(a) shows white regions the size of which is proportional to the value of P_{jk} . Heuristically, the combination of color appearances and visualizations of their frequencies in Fig. 3(a) suggests a way of labeling nodes. Fig. 3(b) shows blue nodes manually assigned as wall regions (class 1) through an user interface.

Nodes labeled in the first stage support a small amount of domain knowledge. Theoretically, the number of nodes selected should be as large as possible⁶⁾. In the second stage, the clustering result is fine-tuned by increasing the number of nodes, e.g., to 60×60 . A fine map is constructed with unlabeled nodes. To assign labels to the new map, the K-Nearest-Neighbors (K-NN) algorithm is deployed. A label is assigned to the new node based on the majority votes of the K objects found from the coarse map. Fig. 3(c) shows a fine map with the labels assigned over nodes, in which the wall components (label 1) are bounded by white contours. Consequently, the wall components are separated from the generic GI color space, as shown in Fig. 4(a). Fig. 4(b) illustrates an example matching the wall colors to pixel data in an original image. The extracted regions suggests the colors that occurred as the GI wall regions are able to verify.

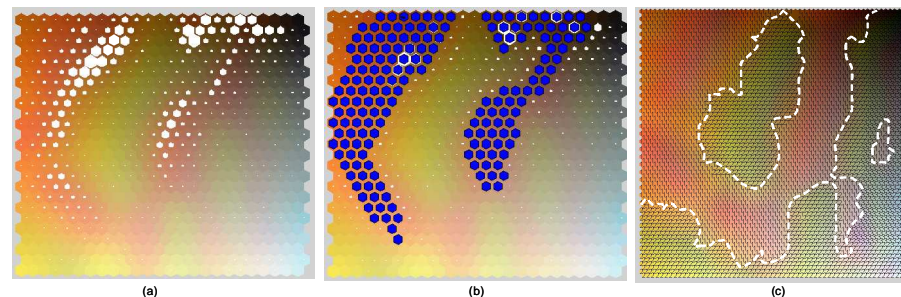


Fig. 3 (a) Visualizing P_{jk} values in white hexagons. (b) Manually assigned labels for the wall components by blue nodes. (c) Clustering result in a fine SOM 60×60 nodes.

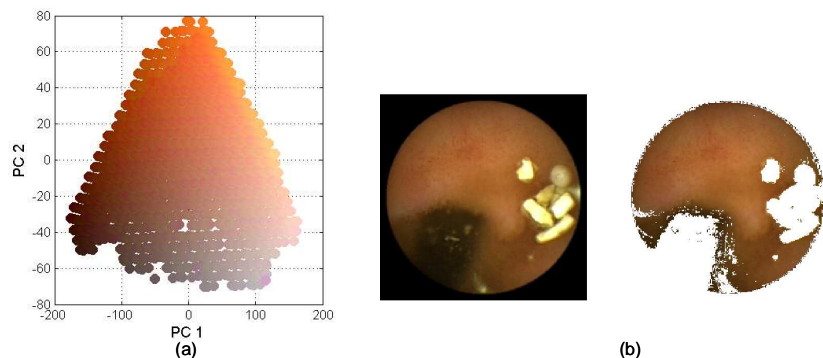


Fig. 4 (a). The wall components expressed in 2-D space by PCA transformation. (b) Left is original image, right is result of the segmented GI wall regions.

3. Capsule Endoscopy (CE) image enhancement using the GI color space

3.1 Related works

To enhance the contrast and the details of the CE image,⁷⁾ and⁸⁾ suggested solutions based on anisotropic diffusions approach. The enhanced images were generated by solving specific diffusion functions. In⁷⁾, based on analyzing the structure tensor of the CE image, two functions, which are adaptively determining the diffusion force according to characteristics of gradient and edge directions, were designed. In⁸⁾, a forward and backward anisotropic diffusion function was utilized in a contrast space. Because of darkness environments in the GI tube, the contrast space can effectively solve in gradient calculation, which is significant to successful of diffusion. However, as a potential problem of the diffusion process, the enhancement results are strongly depending on predetermined parameters in diffusivity functions. In term of the clinical application, the current CE diagnostic system (RapidReader Version 6.0⁴⁾, supported elegantly enhancement functions, named as FICE (Flexible spectral Imaging Color Enhancement) mode. Originally, FICE is developed by Fujinon Ltd.¹¹⁾ for proper conventional endoscopy. FICE images are represented by a four-color vector: $[B_1, B_2, G, R]$. B_1 is normally at a lower end of a blue range (400–430nm), chosen so because of the increased blood absorption in abnormal region. Particularly, this potentially can emphasis regions of higher blood fraction (ulcers, haemorrhages, dense vascular networks characteristic of angiogenesis, cancer).

3.2 Histogram equalization in the proposed GI color space

Often the enhancement of certain features in images is accompanied by undesirable effects. This may cause of over-diagnostics or misunderstanding type of abnormal regions. For example, because FICE images are represented in false colors (e.g. B1/R, B2/R G/R) resulting in color gamut unfamiliar to the clinicians. Without proper training such images are difficult to interpret. Different from previous works, our main objective for image enhancement approaches is that we try to preserve color tones of the original image. This also responds to examining doctor's requirement that colors and texture of inner wall near abnormality should be preserved. With the proposed GI color space, a prior information to identify the useful color gamut is available, therefore our enhancement task is to maximize the information conveyed from the image to examining doctors. This task is deal with by distributing the color data in an original image as uniformly as possible over available color tones in the GI space.

Given a GI color space G (e.g. as shown in Fig. 4(a)), distributions of pixel data of a ROI is denoted by f . $f(x, y)$ is in a range:

$$f(x, y) = \{L_1 < a < L_2; M_1 < b < M_2\} \quad (5)$$

Where a, b is pixel data in the space G . L_1, L_2 and M_1, M_2 are minimum and maximum values of distribution f in PC 1 and PC 2 axes, respectively. Because the space G is constructed from a large VCE sequences, it provides a maximum prior information about available colors in range L_1, L_2 and M_1, M_2 . Therefore, the enhancement task becomes giving the target image a flat distribution in the current range. This is similar to the aim of the conventional histogram equalization technique, which is to distribute the intensity information uniformly over the available intensity levels. The target image $g(x, y)$ can be computed using the following cascaded transformation:

$$g(x, y) = T^{-1}[O(f(x, y))] \quad (6)$$

where $O(\cdot)$ and $T(\cdot)$ are *cdf* functions. $O(\cdot)$ is build from each dimension of original distribution $f(\cdot)$, while $T(\cdot)$ is established based on a uniform data (typically, a uniform white noise). $O(\cdot)$ and $T(\cdot)$ functions are normalized with levels in range L_1, \dots, L_2 (or M_1, \dots, M_2). The entire process of the proposed technique is illustrated by the example in Fig. 5. From the ROI in Fig. 5(a), pixel data are transformed and plotted in 2-D space of the GI wall color components. As depicted in Fig. 5(b), the dotted-blue line in the center graph expresses the boundary of the wall components, while the pixel data boundary is denoted by the solid-blue line. Distribution $f(\cdot)$ is denoted by blue

lines in the histograms on each axis shown in the left and bottom panels of the figure. The enhanced image is illustrated in Fig. 5(c). The red lines in Fig. 5(b) show the transformed data, thus confirming that the histograms are "flat" in the local sense.

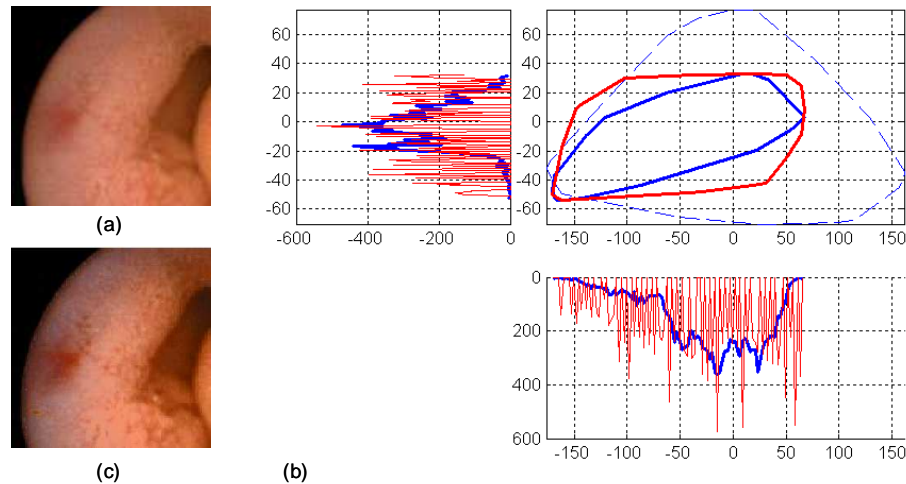


Fig.5 Image Enhancement Technique. (a). Original ROI. (b). Data distribution in the proposed color space. (See text for details). (c). The enhanced image

4. Experimental Results

To validate the proposed enhancement technique, 60 image pairs (each containing original and enhanced images) were prepared for evaluation. The ROIs are extracted from original images with windows of size 128×128 pixels. These ROIs include known types of abnormal regions, such as angiodysplasia, erosion, erythematous, and ulcers. Fig. 6 shows enhanced images by proposed method and FICE images at different modes. For erosion or angiodysplasia images (Case 2 and Case 3) in Fig. 6, FICE images #2 obtains quite good results. This is similar to evaluations in¹¹⁾ that FICE modes images obtain a good performance for bleeding images. However, for other types of abnormal regions, such as Case 1 (Ulcer) and Case 4 (Polyp), FICE images are unclear even compared to original images. As shown in Fig. 6, our proposed method obtains effective

ness for all cases. It implies that our proposed method are more reliable than FICE modes, particularly in aspect of various type of abnormal images.

Table 2 Score distributions in the evaluations by five examiners

Σ Score in an eval.	12	15	16	17	18	19	20	21	22	23	Total
Count	2	8	9	11	7	8	5	7	1	2	60
Percentage (%)	3	13	15	18	12	13	8	12	2	3	100
Above baseline (%)	84%										

For qualitative evaluation, comparisons between the enhanced and original images are assessed at five levels: damaging, worse, ineffective, better and very clear. Scores are assigned from 1 for damaging, to 5 for the very clear level. Support from five examining doctors, all experts in gastroenterology, was included in implementing these evaluations. The baseline is established at the ineffective level, where abnormal regions in the enhanced image and the original image are identical. Table 2 provides further detail by giving the score distributions, in which 84% of the evaluations have a score above the baseline level; only in 2 cases are the enhanced images worse than the original images. Moreover, inspired by conventional histogram equalization, the proposed technique also offers an advantage in terms of computational time.

5. Conclusions

The complete process for generating the GI color space was explained in this paper. The GI wall and non-wall color components are separated in the proposed GI color space using a two stage clustering scheme. The clustering task is based on visualizing similar colors and their distributions using the SOM technique. Utilizing the proposed color space, a technique for image enhancement was described. This technique is able to limit over-diagnosis, that is, to retain the natural color tones of the original image. Experiments confirmed that in 84% of the cases, the enhanced image is clearer than the original image.

The GI color space suffers from requirements to validate its accuracy. Several directions may be explored to solve this issue in future works, such as verifying the consistency of the GI space with different types of datasets; or evaluating the performance of wall regions segmented from original images. For the image enhancement technique, the current transformation implemented in separated axes of the GI color space, thus it lost

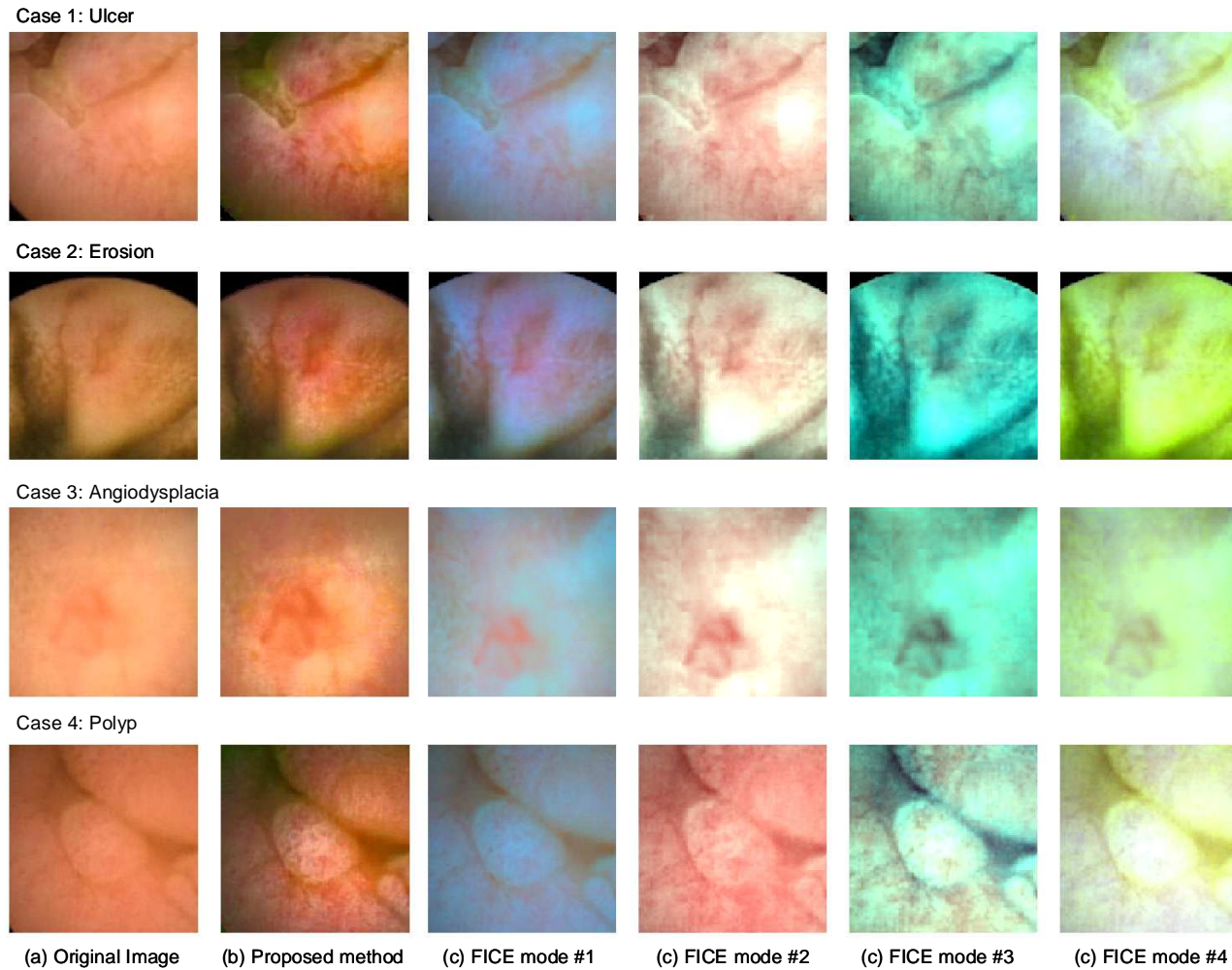


Fig. 6 Comparative results between proposed method and FICE images with four cases of abnormal regions.

correlation between dimensions. These limitations and sparse data problems of histogram equalization technique were mentioned in¹⁾ or¹²⁾. These works suggest us to further research for CE images. Regarding performance evaluation, more aspects such as the best

choice selections, consensus of evaluations between examining doctors, statistical test to verify consistency in evaluation results are implemented in our future works.

References

- 1) Bassiou, N. and Kotropoulos, C.: Color image histogram equalization by absolute dicounting back-off, *Computer Vision and Image Understanding*, Vol.107, pp.108–202 (2007).
- 2) Bonnel, J., Khademi, A., Krishnan, S. and Ioana, C.: Small bowel image classification using cross-co-occurrence matrices on wavelet domain, *Biomedical Signal Processing and Control*, Vol.4, No.1 (2009).
- 3) Cunha, J. P.S., Coimbra, M., Campos, P. and Soares, J.M.: Automated Topographic Segmentation and Transit Time Estimation in Endoscopic Capsule Exams, *IEEE Trans. on Medical Imaging*, Vol.27, pp.19–27 (2008).
- 4) Given Imaging Ltd.: RAPID Software Product, <http://www.givenimaging.com/en-us/HealthCareProfessionals/Products/Pages/Software.aspx> (2009).
- 5) Iddan, G., Meron, G., Glukovsky, A. and Swain, P.: Wireless Capsule Endoscope, *Nature*, Vol.405, p.417 (2000).
- 6) Kohonen, T.: *Self-Organized Maps*, Springer-Verlag, Heidelberg, Berlin, (Third Edition, 2001).
- 7) Li, B. and Meng, M.: Wireless Capsule Endoscopy Images Enhancement by Tensor Based Diffusion, *In Proceeding of International Conference on Engineering in Medicine and Biology Society* (2006).
- 8) Li, B. and Meng, M.: Wireless Capsule Endoscopy Images Enhancement using Contrast Driven Forward and Backward Anisotropic Diffusion, *In Proceeding of International Conference on Image Processing* (2007).
- 9) Mackiewicz, M., Berens, J. and Fisher, M.: Wireless Capsule Endoscopy Color Video Segmentation, *IEEE Trans. on Medical Imaging*, Vol.27, No.12, pp.1769–1781 (2008).
- 10) M.Coimbra and Cunha, J. P.S.: MPEG-7 visual descriptors - Contributions for automated feature extraction in Capsule Endoscopy, *IEEE Trans. Circuits and Systems for Video Technology*, Vol.16, No.5, pp.628–637 (2006).
- 11) Mouri, R., Yosida, S., Tanaka, S., Oka, S., Yoshihara, M. and Chayama, K.: Evaluation and validation of computed virtual chromoendoscopy in early gastric cancer, Vol.69, No.6 (2009).
- 12) Pichon, E., Niethammer, M. and Saprio, G.: Color Hisogram equalization through mesh deformation, *Proceeding of International Conference on Image Processing 2003* (2003).
- 13) SOM Toolbox: <http://www.cis.hut.fi/somtoolbox/> (2003).
- 14) Vu, H., Echigo, T., Sagawa, R., , Yagi, K., Shiba, M., Higuchi, K., Arakawa, T. and Yagi, Y.: Controlling the Display of Capsule Endoscopy Video for Diagnostic Assistance, *IEICE Trans. on Information and Systems*, Vol.E92-D, No.3, pp.512–528 (2009).